



Up-to-date Questions and Answers from authentic resources to improve knowledge and pass the exam at very first attempt. ---- Guaranteed.



ACNPC-AG MCQs
ACNPC-AG TestPrep
ACNPC-AG Study Guide
ACNPC-AG Practice Test
ACNPC-AG Exam Questions



killexams.com

Nursing

ACNPC-AG

AACN Acute Care Nurse Practitioner (Adult-Gerontology)

ORDER FULL VERSION

<https://killexams.com/pass4sure/exam-detail/ACNPC-AG>



Question: 1027

A patient who has undergone a renal transplant is presenting with signs of acute rejection. Which of the following laboratory findings would be most indicative of a rejection episode?

- A. Decreased serum creatinine
- B. Elevated serum potassium
- C. Decreased urine output
- D. Elevated serum creatinine

Answer: D

Explanation: An elevated serum creatinine level is a common indicator of acute rejection in transplant patients, reflecting impaired renal function.

Question: 1028

A patient undergoing immunotherapy for melanoma presents with new-onset cough, fever, and dyspnea. A CT scan reveals ground-glass opacities in the lungs. What should be the nurse practitioner's primary concern regarding this patient's condition?

- A. Tumor progression
- B. Electrolyte imbalance
- C. Pneumonitis
- D. Myocarditis

Answer: C

Explanation: Pneumonitis is a common side effect of immune checkpoint inhibitors and presents with respiratory symptoms and characteristic imaging findings. Prompt recognition and management are crucial to prevent severe complications.

Question: 1029

A 72-year-old man with diabetes and hypertension presents with sudden onset of right-sided weakness and facial droop. CT scan shows a left-sided hemorrhagic stroke. What is the most likely etiology of his stroke?

- A. Hypertensive hemorrhage
- B. Atrial fibrillation
- C. Cerebral venous thrombosis
- D. Ruptured aneurysm

Answer: A

Explanation: Hypertensive hemorrhage is a common cause of intracerebral hemorrhage in patients with

long-standing hypertension, particularly in older individuals.

Question: 1030

A 65-year-old man with chronic heart failure presents with new-onset chest pain and dyspnea. His ECG shows ST segment depression. What is the most appropriate diagnostic test to further evaluate his condition?

- A. Coronary angiography
- B. Cardiac MRI
- C. Chest X-ray
- D. Echocardiogram

Answer: A

Explanation: In a patient with new-onset chest pain and ECG changes suggestive of ischemia, coronary angiography is warranted to evaluate for significant coronary artery disease as the underlying cause.

Question: 1031

A patient with a solid tumor is being treated with a new monoclonal antibody that targets specific tumor antigens. Which of the following mechanisms of action is most characteristic of this treatment modality?

- A. Induction of apoptosis through DNA damage
- B. Enhancing immune response against tumor cells
- C. Blocking angiogenesis by inhibiting VEGF
- D. Direct cytotoxicity to rapidly dividing cells

Answer: B

Explanation: Monoclonal antibodies enhance the immune response against tumor cells by marking them for destruction by immune effector cells.

Question: 1032

A nurse is monitoring a patient receiving chemotherapy who develops a blistering rash on the trunk and extremities. Considering the patient's medication history, which of the following conditions should be suspected?

- A. Stevens-Johnson Syndrome
- B. Drug-induced hypersensitivity
- C. Contact dermatitis
- D. Psoriasis

Answer: A

Explanation: The presentation of blistering rash in the context of chemotherapy suggests Stevens-Johnson Syndrome, particularly if there are mucosal surface involvements. Drug-induced hypersensitivity can cause similar rashes but is less specific.

Question: 1033

In managing a patient with distributive shock due to septicemia, which of the following is a key goal of fluid resuscitation?

- A. Achieving a urine output of 30 ml/hour
- B. Normalizing blood glucose levels
- C. Reducing heart rate to below 100 bpm
- D. Increasing central venous pressure to over 10 mmHg

Answer: A

Explanation: A urine output of 30 ml/hour is a common target in fluid resuscitation to ensure adequate organ perfusion and kidney function.

Question: 1034

A patient with COPD exacerbation is receiving oxygen therapy via a nasal cannula. Which of the following findings would indicate adequate oxygenation and ventilation during treatment?

- A. Patient tolerance of the oxygen device
- B. Decreased respiratory effort
- C. Peak flow rate within normal limits
- D. Oxygen saturation (SpO₂) greater than 92%

Answer: D

Explanation: An oxygen saturation greater than 92% indicates adequate oxygenation. Monitoring this is essential in managing patients with COPD exacerbations.

Question: 1035

A 50-year-old man with a history of chronic alcohol use presents with acute abdominal pain and vomiting. His serum lipase is markedly elevated. Which of the following is the most likely underlying cause of his acute pancreatitis?

- A. Gallstones
- B. Hyperlipidemia
- C. Alcohol consumption
- D. Medication-induced

Answer: C

Explanation: In this case, the patient's chronic alcohol use is the most likely cause of his acute pancreatitis, especially when presenting with elevated lipase levels.

Question: 1036

During a health fair, a nurse practitioner encounters a patient hesitant to participate in preventive screenings due to fear of potential findings. Which approach could best facilitate a productive conversation about the importance of screening?

- A. Highlighting the risks of not knowing one's health status
- B. Emphasizing the potential for early detection and treatment
- C. Providing statistics on the low incidence of false positives
- D. Reassuring the patient that most findings are benign

Answer: B

Explanation: Emphasizing early detection and treatment can help alleviate fears and motivate patients to participate in necessary screenings.

Question: 1037

A patient with a recent viral infection presents with chest pain and is diagnosed with myocarditis. Which of the following treatments is contraindicated?

- A. Antivirals
- B. Corticosteroids
- C. Beta-blockers
- D. Diuretics

Answer: B

Explanation: Corticosteroids are contraindicated in viral myocarditis as they can worsen the condition and do not have proven benefit.

Question: 1038

A 65-year-old male with a history of congestive heart failure presents with edema, hyponatremia, and concentrated urine. What condition does this presentation most likely indicate?

- A. SIADH
- B. Heart failure exacerbation
- C. Diabetes insipidus
- D. Cushing's syndrome

Answer: A

Explanation: The presence of edema, hyponatremia, and concentrated urine suggests SIADH, where excess water retention leads to dilutional hyponatremia.

Question: 1039

Which of the following patients is at the highest risk for developing contrast-associated nephropathy (CAN) after receiving intravenous contrast for imaging studies?

- A. A 50-year-old with well-controlled hypertension
- B. A 30-year-old with a history of asthma
- C. A 65-year-old with type 2 diabetes and a GFR of 50 mL/min
- D. A 40-year-old healthy individual with no comorbidities

Answer: C

Explanation: Patients with diabetes and reduced renal function (GFR < 60 mL/min) are at significantly higher risk for CAN due to their compromised renal perfusion and function, making them susceptible to nephrotoxic effects of contrast agents.

Question: 1040

A nurse is caring for a patient with a deep venous thrombosis who has developed a painful, swollen leg with a red, warm area at the site. Which of the following complications should the nurse be most vigilant about?

- A. Septicemia
- B. Pulmonary embolism
- C. Lymphedema
- D. Chronic venous insufficiency

Answer: B

Explanation: Pulmonary embolism is a serious complication of deep venous thrombosis, where a clot dislodges and travels to the lungs, potentially leading to severe respiratory distress or death.

Question: 1041

A patient with severe aortic stenosis is being considered for surgical intervention. Which of the following findings on echocardiogram would indicate the need for urgent surgical management?

- A. Left ventricular hypertrophy
- B. Asymptomatic status with normal exercise tolerance
- C. Moderate mitral regurgitation
- D. Severe systolic dysfunction with an ejection fraction <50%

Answer: D

Explanation: Severe systolic dysfunction with reduced ejection fraction (<50%) is a critical indication for surgical intervention in aortic stenosis, regardless of symptoms.

Question: 1042

A patient with interstitial lung disease presents with progressive dyspnea on exertion and a dry cough. Which of the following findings on physical examination would be most consistent with this diagnosis?

- A. Fine inspiratory crackles
- B. Dullness to percussion
- C. Wheezing
- D. Stridor

Answer: A

Explanation: Fine inspiratory crackles are characteristic of interstitial lung disease and indicate the presence of abnormal lung parenchyma.

Question: 1043

A 68-year-old woman with a history of chronic headache and dizziness undergoes a brain MRI that shows a mass in the posterior fossa. Which of the following conditions is most likely indicated by this finding?

- A. Acoustic neuroma
- B. Meningioma
- C. Metastatic tumor
- D. Cerebellar infarct

Answer: A

Explanation: An acoustic neuroma, a benign tumor on the vestibulocochlear nerve, is commonly located in the posterior fossa and can present with headaches and dizziness.

Question: 1044

A patient with a history of heart failure presents with acute cardiogenic shock. Which of the following findings would most likely be present on physical examination?

- A. Warm and dry skin
- B. Normal heart sounds
- C. Decreased pulmonary capillary wedge pressure
- D. Jugular venous distension

Answer: D

Explanation: Jugular venous distension is indicative of fluid overload and right-sided heart failure commonly seen in cardiogenic shock.

Question: 1045

In a patient with a solid tumor undergoing chemotherapy, what is the most appropriate strategy to manage potential medication-induced myelosuppression?

- A. Administer antiemetics preemptively
- B. Use prophylactic anticoagulation
- C. Increase oral fluid intake
- D. Monitor complete blood counts frequently

Answer: D

Explanation: Frequent monitoring of complete blood counts is crucial for early detection and management of myelosuppression during chemotherapy.

Question: 1046

Which of the following statements regarding hepatitis B virus (HBV) infection is true, particularly in the context of acute liver failure?

- A. Co-infection with hepatitis D virus worsens the prognosis of HBV.
- B. Acute liver failure is common in chronic HBV infection.
- C. Acute HBV infection is usually asymptomatic.
- D. Presence of HBsAg indicates cleared infection.

Answer: A

Explanation: Co-infection with hepatitis D virus can lead to more severe liver disease and worsen the prognosis in patients with HBV.

Question: 1047

An 80-year-old woman with a history of hypertension and diabetes presents with a sudden onset of severe headache, confusion, and left-sided weakness. A CT scan reveals a subarachnoid hemorrhage. Which of the following complications should be monitored closely in this patient?

- A. Cerebral vasospasm
- B. Hydrocephalus
- C. All of the above
- D. Seizures

Answer: C

Explanation: Patients with subarachnoid hemorrhage are at risk for multiple complications, including cerebral vasospasm, hydrocephalus due to blood obstructing CSF flow, and seizures.

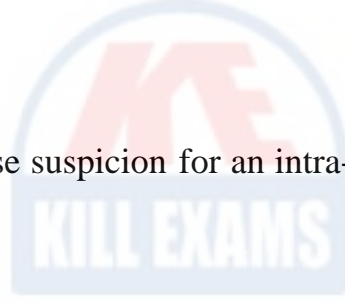
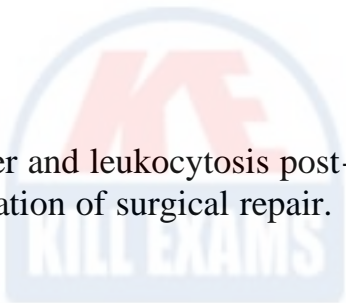
Question: 1048

A patient post-abdominal aortic aneurysm repair develops a fever and leukocytosis. Which of the following complications should be most immediately considered?

- A. Aortic rupture
- B. Pulmonary embolism
- C. Intra-abdominal abscess
- D. Renal failure

Answer: C

Explanation: Fever and leukocytosis post-operatively raise suspicion for an intra-abdominal abscess, a potential complication of surgical repair.



Killexams.com is a leading online platform specializing in high-quality certification exam preparation. Offering a robust suite of tools, including MCQs, practice tests, and advanced test engines, Killexams.com empowers candidates to excel in their certification exams. Discover the key features that make Killexams.com the go-to choice for exam success.



Exam Questions:

Killexams.com provides exam questions that are experienced in test centers. These questions are updated regularly to ensure they are up-to-date and relevant to the latest exam syllabus. By studying these questions, candidates can familiarize themselves with the content and format of the real exam.

Exam MCQs:

Killexams.com offers exam MCQs in PDF format. These questions contain a comprehensive collection of questions and answers that cover the exam topics. By using these MCQs, candidate can enhance their knowledge and improve their chances of success in the certification exam.

Practice Test:

Killexams.com provides practice test through their desktop test engine and online test engine. These practice tests simulate the real exam environment and help candidates assess their readiness for the actual exam. The practice test cover a wide range of questions and enable candidates to identify their strengths and weaknesses.

Guaranteed Success:

Killexams.com offers a success guarantee with the exam MCQs. Killexams claim that by using this materials, candidates will pass their exams on the first attempt or they will get refund for the purchase price. This guarantee provides assurance and confidence to individuals preparing for certification exam.

Updated Contents:

Killexams.com regularly updates its question bank of MCQs to ensure that they are current and reflect the latest changes in the exam syllabus. This helps candidates stay up-to-date with the exam content and increases their chances of success.