



Up-to-date Questions and Answers from authentic resources to improve knowledge and pass the exam at very first attempt. ---- Guaranteed.



ABTS MCQs
ABTS Exam Questions
ABTS Practice Test
ABTS TestPrep
ABTS Study Guide



killexams.com

ABTS

ABTS

Congenital Cardiac Surgery (CHS Part I)
Written

ORDER FULL VERSION

<https://killexams.com/pass4sure/exam-detail/ABTS>



Question: 111

A 2-week-old infant presents with cyanosis and a harsh systolic murmur. The echocardiogram reveals transposition of the great arteries. Which embryologic failure is most likely to have occurred?

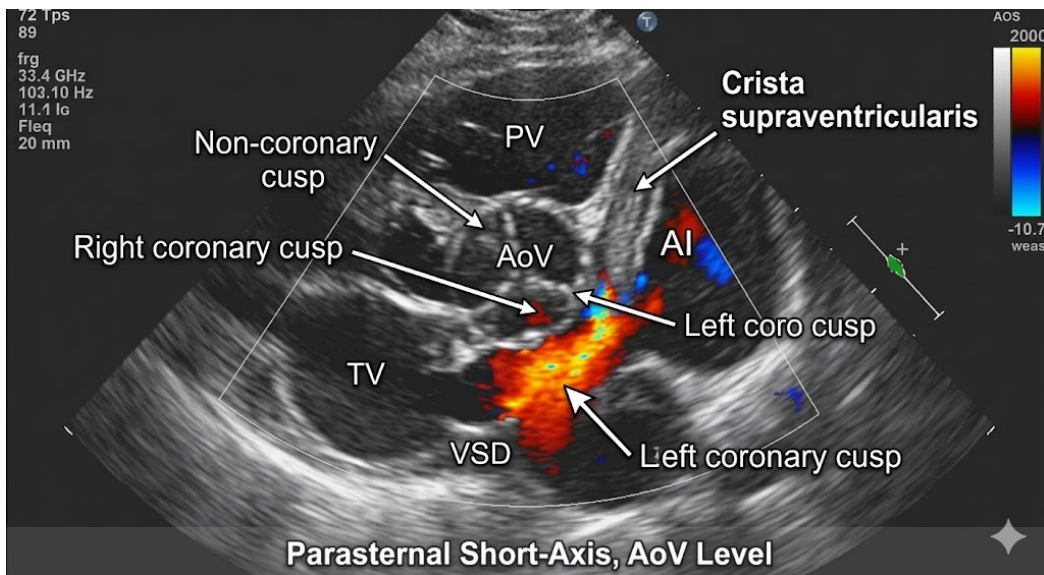
- A. Abnormal fusion of the endocardial cushions
- B. Failure of the atrial septum to form
- C. Malformation of the bulbus cordis
- D. Improper development of the conotruncal septum

Answer: D

Explanation: Transposition of the great arteries results from improper development of the conotruncal septum, which fails to correctly separate the aorta and pulmonary artery. This leads to a situation where the systemic and pulmonary circulations are parallel rather than in series.

Question: 112

A 3-year-old girl with holosystolic murmur and Qp:Qs 2.5:1 on oximetry undergoes pre-op imaging. The parasternal short-axis color Doppler frame reveals a high perimembranous VSD just below the aortic and pulmonary valves with left-to-right turbulent flow, aortic cusp prolapse into the defect, and mild AI jet. ECG shows incomplete RBBB, echo LVEDD z-score +3.5. What VSD subtype is shown, and what CHS-specific surgical nuance is critical to avoid aortic regurgitation progression?



- A. Perimembranous VSD with aortic cusp support using patch-retaining suture
- B. Inlet VSD adjacent to AV valves
- C. Muscular trabecular VSD
- D. Subarterial VSD with double-patch closure

Answer: A

Explanation: Perimembranous ventricular septal defect (70-80% of VSDs) lies in the membranous septum below the aortic (often non-coronary) and tricuspid valves, prone to aortic cusp prolapse and AI due to Venturi effect, visualized in parasternal short-axis at AV level with defect medial to crista and cusp herniation on color Doppler. Differentiates from muscular (apical/multiple, muscular rims), subarterial/supracristal (outlet beneath semilunar valves, aortic prolapse more common), inlet (near TV in AV canal). Surgery uses Dacron/Gore-Tex patch with everting mattress sutures secured away from aortic annulus; for prolapse, cusp plication or patch extension supports leaflet to prevent progression to severe AI (risk 20% untreated).

Question: 1113

A patient with pulmonary hypertension is being evaluated for Fontan candidacy. Which of the following PVRi values would most likely disqualify the patient?

- A. 4 Wood units/m²
- B. 6 Wood units/m²
- C. 3 Wood units/m²
- D. 2 Wood units/m²

Answer: B

Explanation: A PVRi value of 6 Wood units/m² would most likely disqualify a patient from Fontan candidacy, as it indicates severely elevated pulmonary vascular resistance, which poses significant risks for postoperative complications.

Question: 1114

During deep hypothermic circulatory arrest for neonatal aortic arch advancement in interrupted aortic arch repair, core temperature reaches 17 degrees Celsius after 20 minutes cooling on cardiopulmonary bypass at 2.4 liters per square meter per minute flow. What hematocrit threshold minimizes sludging during 60 minutes arrest?

- A. 20-24 percent
- B. 28-32 percent
- C. No specific target required
- D. Greater than 35 percent
- E. Less than 25 percent

Answer: B

Explanation: Optimal prime hematocrit 28-32 percent during deep hypothermic circulatory arrest balances oxygen-carrying capacity with microcirculatory rheology, preventing red cell sludging in cerebral and spinal cord capillary beds during 60-minute arrest durations. Ultra-filtration concentrates to target during cooling phase on cardiopulmonary bypass at pH-stat management, reducing inflammatory mediator release and improving 1-year neurodevelopmental scores (Mental Development Index 90 versus 75 below 28 percent), as validated by Boston Circulatory Arrest Study cohort data emphasizing anemia neurotoxicity at hypothermia.

Question: 1115

Situs inversus totalis with mirror-image dextrocardia and normal heart (Kartagener variant, primary ciliary dyskinesia) presents with recurrent pneumonia. Surgical irrelevance of inversion reflects preserved which asymmetry pathway despite global mirror?

- A. Nodal cilia rotation
- B. Bulboventricular looping
- C. Neural crest migration
- D. Secondary field addition
- E. Pharyngeal signaling

Answer: B

Explanation: Situs inversus maintains cardiac solitus-like segmental anatomy (S,L,L) mirrored; normal heart common (7% CHD), with bronchiectasis/sinusitis from immotile cilia failing leftward nodal flow, not impacting conotruncal neural crest.

Question: 1116

A patient with a significant left-to-right shunt has a Qp/Qs ratio of 5:1. What is the most appropriate next step in management?

- A. Surgical closure of the shunt
- B. Observation
- C. Administration of anticoagulants
- D. Initiation of diuretics

Answer: A

Explanation: In a patient with a Qp/Qs ratio of 5:1, the most appropriate next step in management is surgical closure of the shunt to prevent complications associated with excessive pulmonary blood flow and potential heart failure.

Question: 1117

Recoarctation aneurysm measuring 2 cm following prior patch repair. What technique excludes the aneurysm?

- A. Balloon angioplasty
- B. Dacron graft exclusion
- C. Observation protocol
- D. Surgical clipping
- E. Bare metal stent

Answer: B

Explanation: Aneurysms exceeding 1.5 cm diameter post-coarctation repair require Dacron graft interposition with exclusion, preserving distal perfusion while eliminating rupture risk.

Question: 1118

VA-ECMO circuit anticoagulation target activated clotting time?

- A. Fibrinogen above 150 milligrams per deciliter
- B. 200-220 seconds
- C. 160-180 seconds
- D. 240-260 seconds
- E. Anti-Xa 0.3-0.5 units per milliliter

Answer: C

Explanation: Venoarterial extracorporeal membrane oxygenation anticoagulation maintains activated clotting time 160-180 seconds with heparin infusion 20-50 units per kilogram per hour, balancing circuit patency (thrombosis 20 percent) and bleeding risk (hemorrhage 30 percent), monitored by thromboelastography and platelet function assay.

Question: 1119

During a Konno procedure for complex subaortic stenosis, the surgeon performs an aortoventriculoplasty. This involves an incision through which of the following structures to enlarge the left ventricular outflow tract?

- A. The anterior leaflet of the mitral valve
- B. The right ventricular free wall only
- C. The interventricular septum and the aortic annulus
- D. The posterior wall of the aorta

Answer: C

Explanation: The Konno procedure is used to enlarge a small aortic annulus and subaortic area. It involves a longitudinal aortotomy that extends across the aortic annulus and into the outlet portion of the interventricular septum. This "gap" is then patched to widen the LVOT, and a prosthetic valve is typically implanted.

Question: 1120

Down syndrome infant with partial AVSD: primum ASD 6 mm, mitral cleft (MR 2+). Repair at 3 months; defect lies how far superior to AV valve plane, distinguishing from secundum?

- A. Coronary sinus (5-8 mm)
- B. Immediately adjacent (0-3 mm)
- C. SVC-SVC junction (20 mm)
- D. Fossa ovalis center (10-15 mm)

Answer: B

Explanation: Ostium primum site is directly above AV cushions without intervening rim; primum ASD mandates open patch with cleft plasty, unlike device-eligible secundum in fossa.

Question: 1121

A newborn with truncus arteriosus is being prepared for surgery. Which of the following is a critical preoperative consideration?

- A. Control of systemic hypertension
- B. Maintenance of ductal patency
- C. Assessment of right ventricular function
- D. Prevention of pulmonary infections

Answer: B

Explanation: Maintenance of ductal patency is critical in the preoperative management of truncus arteriosus, as the ductus arteriosus provides necessary blood flow to the pulmonary arteries and lower body until surgical correction can be performed.

Question: 1122

Neonate with critical aortic stenosis (valve area $0.4 \text{ cm}^2/\text{m}^2$, LV EF 35%, endocardial fibroelastosis) on echo. Fetal valvuloplasty failed. What initial intervention assesses biventricular repair potential?

- A. Norwood stage I palliation
- B. Hybrid LVOT stenting
- C. Balloon aortic valvuloplasty (BAV)
- D. Ross-Konno procedure

Answer: C

Explanation: Neonatal BAV (transfemoral/umbilical) reduces gradient (>50%), improves EF, and buys time (median 1 year) to assess LV function for biventricular repair vs single-ventricle path; 50% progress to Ross/HLHS.

Question: 1123

Junctional ectopic tachycardia refractory to cooling and sedation, rate 190 beats per minute. Second-line therapy?

- A. Propranolol 0.5 milligrams per kilogram slow IV
- B. Amiodarone infusion
- C. Ivabradine 0.15 milligrams per kilogram
- D. Verapamil 0.1 milligrams per kilogram
- E. Landiolol 0.1 milligrams per kilogram per hour

Answer: B

Explanation: Amiodarone infusion 5-10 micrograms per kilogram per minute controls refractory junctional ectopic tachycardia by multichannel blockade suppressing automaticity and prolonging refractoriness, achieving rate below 150 beats per minute in 80 percent without hemodynamic compromise.

Question: 1124

A 2-year-old child with a perimembranous VSD is undergoing surgery. The surgeon notes that the septal leaflet of the tricuspid valve has multiple fibrous attachments (aneurysmal tissue) partially occluding the defect. Hemodynamic measurements show a peak gradient across the VSD of 70 mmHg with a systemic blood pressure of

90/60 mmHg. What is the most likely hemodynamic consequence of this aneurysmal tissue?

- A. Increase in the volume of the left-to-right shunt
- B. Transformation into a right-to-left shunt
- C. Natural history of spontaneous closure or restrictive flow
- D. Requirement for tricuspid valve replacement

Answer: C

Explanation: Perimembranous VSDs often decrease in size or become "restrictive" due to the formation of an "aneurysm of the membranous septum." This is actually tricuspid valve tissue (septal leaflet) that gets "sucked" into the defect and adheres to the edges. A high gradient (like 70 mmHg in a patient with a systemic pressure of 90) indicates that the defect is small and restrictive, often allowing the surgeon to defer surgery if the patient is asymptomatic and has no chamber enlargement.

Question: 1125

The "Ligamentum Arteriosum" is the fibrous remnant of which embryonic structure?

- A. Right fourth pharyngeal arch artery
- B. Left sixth pharyngeal arch artery
- C. Left fourth pharyngeal arch artery
- D. Right sixth pharyngeal arch artery

Answer: B

Explanation: The ductus arteriosus is derived from the distal portion of the left 6th pharyngeal arch artery. After birth, when it closes and fibroses, it becomes the

ligamentum arteriosum. The proximal portion of the 6th arch forms the proximal pulmonary arteries.

Question: 1126

A 3.5 kilogram neonate with critical coarctation of the aorta and ventricular septal defect dependent on patent ductus arteriosus for lower body perfusion presents with metabolic acidosis pH 7.28, base excess -12, and femoral pulses absent.

Prostaglandin E1 infusion initiation protocol?

- A. 0.01 micrograms per kilogram per minute
- B. 0.2 micrograms per kilogram per minute
- C. 0.05 micrograms per kilogram per minute
- D. 0.4 micrograms per kilogram per minute
- E. 0.1 micrograms per kilogram per minute

Answer: C

Explanation: Prostaglandin E1 (alprostadil) infusion at 0.05 micrograms per kilogram per minute intravenously maintains ductal patency in ductal-dependent systemic lesions like coarctation by stimulating cyclic adenosine monophosphate-mediated smooth muscle relaxation of ductal tissue, restoring lower body perfusion within 15-30 minutes evidenced by palpable femoral pulses, resolution of acidosis, and pre/post-ductal saturation equalization. Titration upward to 0.1 micrograms per kilogram per minute addresses incomplete response while monitoring for apnea (10 percent risk requiring intubation readiness), cortical hyperostosis, or seizure (1 percent), with central line administration minimizing peripheral irritation and dose reduction to 0.01-0.025 micrograms per kilogram per minute post-surgical repair to facilitate ductal constriction.

Question: 1127

A 5-year-old child is being evaluated for pulmonary vascular resistance (PVR). If the pulmonary artery pressure is 35 mmHg and the pulmonary capillary wedge pressure is 10 mmHg, what would be the expected PVR if the flow rate (Q) is 2 L/min?

- A. $PVR = \frac{(35+10)}{2}$; elevated PVR
- B. $PVR = \frac{(35-10)}{2}$; elevated PVR
- C. $PVR = \frac{(35-10)}{2}$; normal PVR
- D. $PVR = \frac{(35+10)}{2}$; normal PVR

Answer: B

Explanation: PVR is calculated using the formula $PVR = \frac{(mPAP - PCWP)}{Q}$, where mPAP is the mean pulmonary artery pressure and PCWP is the pulmonary capillary wedge pressure. In this case, the calculation yields an elevated PVR, indicating increased resistance in the pulmonary circulation.

Question: 1128

A 7-month-old with a large VSD has Qp/Qs 2.9, pulmonary venous saturation 99%, and systemic saturation 95%. Which additional finding would most strongly support a large net left-to-right shunt?

- A. Elevated pulmonary artery oxygen saturation relative to mixed venous saturation
- B. Markedly reduced systemic arterial saturation with unchanged pulmonary venous saturation
- C. Equal systemic and pulmonary arterial oxygen saturations
- D. Lower-than-normal pulmonary venous oxygen saturation

Answer: A

Explanation: In a significant left-to-right shunt, oxygenated blood enters the right heart and pulmonary artery, raising pulmonary artery saturation above mixed venous saturation. This is one of the classic hemodynamic clues to excess pulmonary flow. Pulmonary venous saturation is usually normal because oxygenation in the lungs is preserved. Markedly reduced systemic saturation would suggest either right-to-left shunting or lung disease rather than a pure left-to-right shunt.



Killexams.com is a leading online platform specializing in high-quality certification exam preparation. Offering a robust suite of tools, including MCQs, practice tests, and advanced test engines, Killexams.com empowers candidates to excel in their certification exams. Discover the key features that make Killexams.com the go-to choice for exam success.



Exam Questions Based on Current Exam Objectives

Killexams.com provides exam questions aligned with the latest official exam objectives and latest syllabus. Our content is reviewed and updated regularly to reflect recent changes announced by certification vendors. By studying these questions, candidates will become cover the structure, difficulty level, and topic coverage of the actual exam, helping them prepare more effectively and efficiently.

Comprehensive Exam MCQs (PDF Format)

Killexams.com offers multiple-choice questions (MCQs) in easy-to-read PDF format, covering all major domains of the exam. Each PDF contains a structured collection of questions and verified answers designed to support focused study. These MCQs help candidates reinforce key concepts, identify knowledge gaps, and improve exam readiness through consistent practice.

Realistic Practice Tests (Online & Desktop)

To support hands-on preparation, Killexams.com provides practice tests through both an Online Test Engine and a Desktop Exam Simulator. These tools are designed to simulate a real exam environment, allowing candidates to practice under exam-like conditions. Performance tracking, test history, and result analysis help users evaluate their progress and focus on areas that need improvement.

Risk-Free Purchase Policy

Killexams.com follows a transparent and customer-friendly purchase policy. If users are not satisfied with the study materials, they may request assistance or a refund in accordance with our published terms and conditions. This policy reflects our commitment to customer satisfaction, fairness, and confidence in our preparation resources.

Regularly Updated Content

Our question bank is reviewed and updated on an ongoing basis to stay aligned with the latest exam outlines and vendor updates. This ensures candidates are studying relevant material and preparing with content that reflects current exam expectations, helping them stay confident and well-prepared.